








RECORD OF METACERCARIAE OF PARAGONIMUS BRAUN, 1899 (PLATYHELMINTHES: TREMATODA) IN THE AMAZON PROVINCE: THE SECOND ALERT OF TREMATODES AS POTENTIAL RISK TO HUMAN HEALTH IN THE STATE OF PARÁ, BRAZIL

Déborah Elena Galvão Martins^{1,2*} ; Israel Hidenburgo Aniceto Cintra¹ ; Silvio Felipe Barbosa Lima³ 
Victória Maria Rodrigues de Sousa¹ ; Flavio de Almeida Alves-Júnior² 

Abstract

In this study we report a new occurrence of *Paragonimus* Braun, 1899 in the Amazon province, recovered from a new host, the semi-terrestrial sesamid crab *Armases benedicti* (Rathbun, 1897). Additionally, we would like to alert the health authorities to the presence of trematodes in the urban area of Belém-PA. The specimens of *A. benedicti* were manually collected on the banks of the Guamá River (01°28'22.6"S; 048°26'49.79"W) in January 2024. We accounted for 42 specimens of *A. benedicti*, with one male showing the presence of an excysted metacercariae of *Paragonimus* sp. in the seminal tube. Despite the low number of individuals, the occurrence of this parasite in the region raises the possible parasitism in other organisms such as mollusks, other crustaceans and fish, which are directly consumed by humans. Thus, this paper focuses in warning the risk of contamination of the population, especially by pulmonary paragonimiasis, however, further studies and new samples are needed to identify this parasite in species level and describe its life cycle in the region.

Keywords: Parasites. *Armases benedicti*. New host interaction. Guamá River. Fish-borne trematodes.

¹Laboratório de Crustáceos (LABCRUS), Instituto Socioambiental e dos Recursos Hídricos (ISARH), Universidade Federal Rural da Amazônia (UFRA), Avenida Presidente Tancredo Neves, nº 2501, Terra Firme, CEP: 66077-830, Belém, Pará, Brasil.

²Universidade Federal do Pará, Núcleo de Ecologia Aquática e Pesca (NEAP), Rua Augusto Corrêa, s/n, Guamá, CEP: 66075-110, Belém, Pará, Brasil. Programa de Pós-Graduação em Ecologia Aquática e Pesca (PPGEAP) da Universidade Federal do Pará (UFPA), Belém, Pará, Brasil.

³Universidade Federal de Campina Grande (UFCG), Centro de Formação de Professores, Unidade Acadêmica de Ciências Exatas e Naturais, Rua Sérgio Moreira de Figueiredo, Casas Populares, Cajazeiras, CEP: 58900-000, Paraíba, Brasil.

*Corresponding author: deborah.martins@ufra.edu.br

Submitted on: 09 Feb. 2024
Accepted on: 25 Mar. 2024
Published on: 05 Apr. 2024

1 Introduction

The transmission of diseases through the consumption of contaminated food is widely observed in underdeveloped and developing countries. This is associated with the deficiency or absence of basic sanitation and low water quality, which is a strong agent for the dissemination of parasites between animals and the population (GIBODA et al., 1991; TOLEDO et al., 2022). Trematodes of the family Paragonimidae Dollfus, 1939 are widely reported in the literature as parasites in several species of invertebrates (intermediate hosts) and vertebrates, including humans (final host) (DIAS et al., 2003). Within this family, the genus *Paragonimus* Braun, 1899 is recorded as the endoparasites of mollusks, crustaceans, fish, birds, rodents, bats, cats, dogs, and humans, which can be parasitized by the consumption of undercooked crab and fish (PHYO MYINT et al., 2020; MARTINS et al., 2023).

Human paragonimiasis is a pulmonary disease that affects millions of people around the world, especially in Africa, Europe and Asia. It is acquired by the presence of some species of *Paragonimus* such as: *P. africanus* Voelker & Vogel, 1965, *P. heterotremus* Chen & Hsia, 1964, *P. kellicotti* Ward, 1908, *P. gondiwanensis* Bayssade-Dufour; Hermette; Šundić & Radujković, 2014; *P. mexicanus* Miyazaki & Ishii, 1968, *P. miyazakii* Kamo, Nishida, Hatsushika & Tomimura, 1961, *P. skrjabini* Chen, 1959, *P. uterobilateralis* Voelker & Vogel, 1965 and *P. westermani* (Kerbert, 1878) Braun, 1899, which cause respiratory problems such as coughing, tuberculosis and lung necrosis. In rare cases, the parasites can affect the central nervous system, causing paralysis, convulsions and brain damage (LEMOS et al., 2007; BLAIR, 2022).

In Brazil, several cases of contamination of domestic animals and humans by trematodes were reported in the literature: Costa et al. (1984), Bogéa et al. (2005), Oliveira et al. (2005), Siqueira Batista et al. (2006), Lemos et al. (2007), Pinto & Melo (2012) and Martins et al. (2023). However, in the Amazon region, especially in the state of Pará, only the papers performed by Benigno et al. (2014) and Martins et al. (2023) reported the presence of trematodes in metacercariae stages as parasites of fish and shrimp respectively, which can lead to risks for human health through inadequate consumption. Based on this, in this study we report the presence of an excysted metacercariae of *Paragonimus* sp. in a new host, the semi-terrestrial sesamid crab *Armases benedicti* (Rathbun, 1897), collected from the urban area of Belém-PA, Brazil. Additionally, we would like to alert the health authorities to the presence of trematodes in the urban area of Belém-PA, with the risk of contamination by trematoda from fish consumption in the region.

2 Material and Methods

The specimens of *A. benedicti* were manually collected in January 2024 on the banks of the Guamá River (01°27'54.2"S; 048°26'02.6"W) (Figure 1), one of the main rivers crossing the city of Belém, in the State of Pará. This river shows highly eutrophic characterization, with muddy and turbid waters, and the strong presence of clay particles in suspension since the domestic waste from the Belém metropolitan area, as well as chemical elements from the factories located along the Guamá River (COSTA et al., 2022; MARTINS et al., 2023).

After the specimens were collected, they were transported alive to the Carcinology laboratory (LABCRUS) of the Federal Rural University of the Amazon (UFRA), where the individuals were identified and sexed. Afterwards, the specimens were dissected in the carapace region under a stereomicroscope to search for parasites in gills, hepatopancreas and gonads. In the specimen that showed trematode, the tissues were removed, transferred to Petri dishes containing saline solution (NaCl 0.85%) and analyzed by means of optical microscopy to determine whether metacercariae were present, by counting and photographing, using a Motic Moticam5® Camera. For the fixation of metacercariae, we used AFA (Acetone - Formaldehyde - Alcohol).

3 Results and Discussion

42 specimens (22 males and 20 females) of *A. benedicti* (Figure 2A) were collected, which only one male showed the presence of one excysted metacercariae of *Paragonimus* sp. in the seminal tube (Figure 2B), this parasite was observed contain 837.92 µm in size (Figure 2C). The presence of metacercariae in invertebrates at the base of the food chain may indicate a risk to the biosafety of the environment, due to strong sewage contamination in the region, directly affecting the organisms that decompose organic matter (i.e. mollusks, shrimps and crabs). The latter become intermediate hosts for trematodes and end up spreading diseases to other hosts, including the human population. According to Doanh; Horii; Nawa (2013), for some species of *Paragonimus*, the stage of metacercariae can be found excysted in semi-terrestrial brachyuran crabs, as the case of *P. proliferus* Hsia & Chen, 1964, however, in order to identify the parasite reported in this paper at species level, further molecular studies are needed, as well as more specimens for later identification.

RECORD OF METACERCARIAE OF PARAGONIMUS BRAUN, 1899 (PLATYHELMINTHES: TREMATODA) IN THE AMAZON PROVINCE: THE SECOND ALERT OF TREMATODES AS POTENTIAL RISK TO HUMAN HEALTH IN THE STATE OF PARÁ, BRAZIL

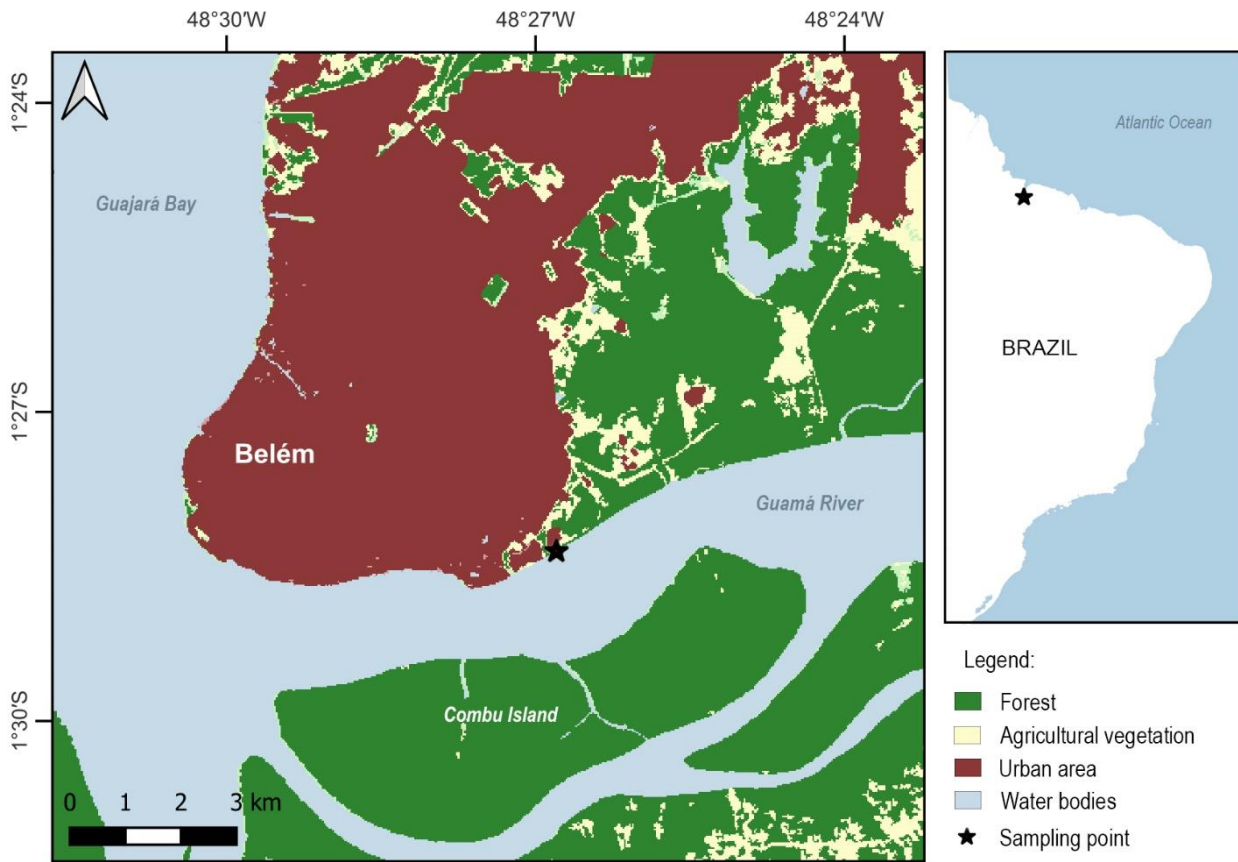


Figure 1. Map indicating the metropolitan region of Belém-PA, Brazil. Black star = sampling point. Land use source: MapBiomas (2023).

In Brazil, several studies in central and southern regions have reported the presence of trematodes in mollusk hosts, especially as endoparasites of the snail species *Melanooides tuberculata* (Müller, 1774), which act as an intermediate host for the species: *Centrocestus formosanus*, *Opisthorchis felinus* (Rivolta, 1884) and *Opisthorchis viverrini* (Poirier, 1886). These species (parasite and host) can be found in urban areas associated with eutrophicated rivers and lakes (PINTO; MELO, 2010; 2012).

Many cases indicating the presence of trematodes in domestic animals are observed in the literature (COSTA et al., 1984; BORAY, 1985, 1986; OLIVEIRA et al., 2005 and references therein); with these parasites causing zoonotic diseases which can lead to the widespread dissemination of these parasites to the environment and other individuals, including humans, who become infected through contact with the feces of these animals (MARTINS et al., 2023).

In studies performed by Chieffi et al. (1990), Dias et al. (1992) and Lemos et al. (2007), observed clinical cases with parasitism by trematodes in humans, with reports of *Ascocotyle* sp. Looss, 1899, *Clonorchis sinensis* (Cobbold, 1875), *Fasciola hepatica* Linnaeus, 1758 and *Paragonimus westermani* (Kerbert, 1878) in the states of Bahia, Minas Gerais, Rio de Janeiro and São Paulo. The first documented case of human paragonimiasis promoted by *P. westermani* was observed in the state of Bahia by Lemos et al. (2007), with a patient presenting pulmonary degradation and tuberculosis acquired through the consumption of contaminated shrimp and fish. Additionally, the direct consumption of undercooked or raw shrimp and fish (i.e. salads, sushi) may cause a risk of contamination by trematoda (PHYO MYINT et al., 2020; MARTINS et al., 2023).

The first contamination of humans by trematode is associated with the consumption of contaminated and undercooked fish, when the parasite completes its life cycle in the definitive host (in organs like the liver, spleen, bladder, lungs and brain).

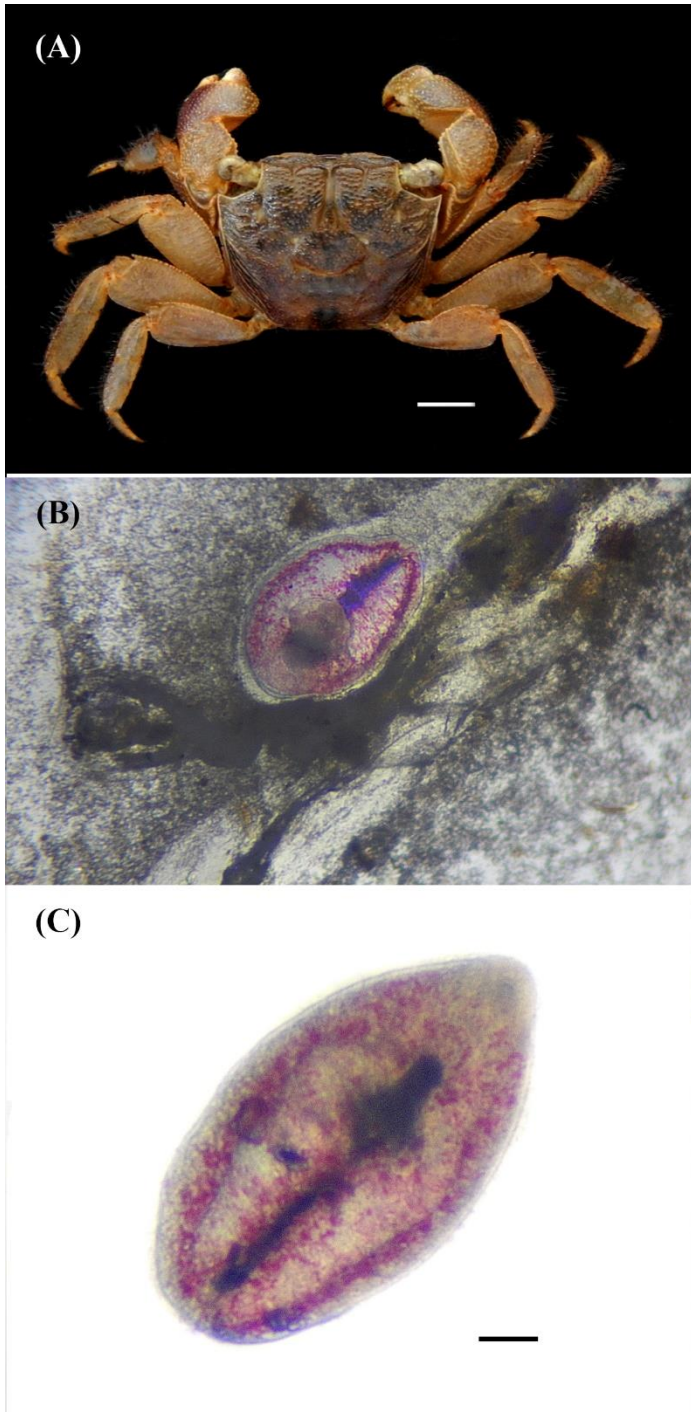


Figure 2. A) The crab host *Armases benedicti* (Rathbun, 1897) (male), B) Metacercariae of *Paragonimus* sp. Braun, 1899 found in the seminal tube of *A. benedicti*, C) *Paragonimus* sp. in the highlighted dorsal view. Scale bars = A) 5 mm and C) 100 μ m.

Later the cysts are released into the environment, where, due to the lack of basic sanitation, the new parasites are free to search for new hosts (intermediate and definitive) in aquatic environments, covering especially mollusks, crustaceans and fish (PHYO MYINT et al., 2020; MARTINS et al., 2023). This case is intensified by the migration of parasitized people to other regions of the world where they introduce parasites into new environments, thus increasing the range of occurrence of the parasite species and raising the number of new parasitized people, hence causing a serious public health issue (DIAS et al., 1992; BELIZARIO et al., 2001).

Studies performed by Doanh et al. (2007; 2016), Sugiyama et al. (2009) Calvopina et al. (2018) and Banzai et al. (2021), reported the presence of *Paragonimus* spp. using invertebrates, especially freshwater crabs, as intermediate hosts. The occurrence of *Paragonimus* sp. in urban areas presents the risk of contamination to other organisms that consume these invertebrates, especially fish, which afterwards will become one of the definitive hosts and be directly consumed by humans. Despite the high level of urbanization and eutrophication of the Guamá River, several shrimp and fish species are commonly consumed by the population (i.e. *Brachyplatystoma rousseauxii* (Castelnau, 1855), *Hypophthalmus marginatus* Valenciennes, 1840, *Plagioscion squamosissimus* (Heckel, 1940) and *Macrobrachium amazonicum* Heller, 1862).

The presence of *Paragonimus* sp. in the city of Belém may be associated with the high urbanization process and the lack of basic sanitation, which can lead to the risk of contamination of the population by the inadequate consumption of fish from the Guamá River.

4 Conclusions

This paper reinforces the warning to health authorities about the presence of *Paragonimus* sp. observed in a new invertebrate host species (*Armases benedicti*) in the urban areas of Belém-PA. From this host, *Paragonimus* sp. can reach fish in the entire food chain and even be consumed by humans. In this case, the parasite can cause serious health issues, especially pulmonary paragonimiasis, resulting from the inadequate consumption of parasitized fish collected in the region.

CREDIT AUTHORSHIP CONTRIBUTION STATEMENT

DEGM, VMRS and FAAJ conceived the research ideas, designed the study and writing the manuscript; IHAC and SFBL performed the first draft of this manuscript and revisions along the main text.

DECLARATION OF INTEREST

The authors declare that they have no known competing financial interests or personal relationships that could have appeared to influence this study.

FUNDING SOURCE

No financial contribution was used for the development of this article.

ACKNOWLEDGEMENTS

The authors would like to thank the National Center for Research and Conservation of Northern Marine Biodiversity - CEPNOR / ICMBio for the support and laboratory for this study. Also, we would like to thank the anonymous reviewers for their precious comments in this manuscript.

REFERENCES

BANZAI, A.; SUGIYAMA, H.; HASEGAWA, M.; MORISHIMA, Y.; KAWAKAMI, Y. *Paragonimus westermani* metacercariae in two freshwater crab species in Kagoshima Prefecture, Japan, as a possible source of infection in wild boars and sika deer. *The Journal of Veterinary Medical Science*, v. 83, n. 3, p. 412-418, 2021. Available from: <https://doi.org/10.1292/jvms.20-0576>

BENIGINO, R.N.M.; KNOFF, M.; MATOS, E.R.; GOMES, D.C.; PINTO, R.M.; SÃO CLEMENTE, S.C. Morphological aspects of *Clinostomidae metacercariae* (Trematoda: Digenea) in *Hoplerytinus unitaeniatus* and *Hoplias malabaricus* (Pisces: Erythrinidae) of the Neotropical region, Brazil. *Anais da Academia Brasileira de Ciências*, v. 86, n. 2, p. 733-744, 2014. Available from: <http://dx.doi.org/10.1590/0001-3765201420130025>

BELIZARIO, J.V.; BERSABE, M.J.; HILOMEN, V.Y.; PALLER, G.V.; BUGAYON, M.G. Intestinal heterophyidiasis: an emerging food-borne parasitic zoonosis in southern Philippines. *The Southeast Asian Journal of Tropical Medicine and Public Health*, v. 32, p. 36-42, 2001. Available from: <https://pubmed.ncbi.nlm.nih.gov/12041601>.

BLAIR, D. Lung flukes of the genus *Paragonimus*: ancient and re-emerging pathogens. *Parasitology*, 149(10), 1286-1295, 2022. Available from: <http://dx.doi.org/10.1017/S0031182022000300>

BOGÉA, T.; CORDEIRO, F.M.; GOUVEIA, J.S. *Melanoides tuberculatus* (Gastropoda: Thiariidae) as intermediate host of Heterophyidae (Trematoda: Digenea) in Rio de Janeiro metropolitan area, Brazil. *Revista do Instituto de Medicina Tropical de São Paulo*, v. 47, n. 2, p. 87-90, 2005. Available from: <https://doi.org/10.1590/S0036-46652005000200005>

BORAY, J.C. Flukes of domestic animals. In: GAAFAR, S.M.; HOWARD, W.E.; MARSH, R.E. (Orgs). *Parasites, pests and predators: Word Animal Sciences*. Volume B2. Glenfield: Elsevier Science Publishers, v. 91, n. 2, 1985. Available from: <https://www.cambridge.org/core/services/aop-cambridge-core/content/view/3034DD6A30FAA1F284152C79B632616/S0031182000057292a.pdf/div-class-title-par-volume-91-issue-2-cover-and-back-matter-div.pdf>. Accessed on: 08 Jan. 2024.

BORAY, J.C. Trematode infections of domestic animals. In: CAMPBELL, W.C.; Rew, R.S. (Orgs). *Chemotherapy of Parasitic Disease*. New York: Plenum Press, 1986.

CALVOPINA, M.; ROMERO-ALVAREZ, D.; RENDON, M.; TAKAGI, H.; SUGIYAMA, H. *Hypolobocera guayaquilensis* (Decapoda: Pseudothelphusidae): A New Crab Intermediate Host of *Paragonimus mexicanus* in Manabí Province, Ecuador. *Korean Journal of Parasitology*, v. 56, n. 2, p. 189-194, 2018. Available from: <https://doi.org/10.3347/kjp.2018.56.2.189>

CHIEFFI, P.; LEITE, O.H.; DIAS, R.M.D.S.; TORRES, D.M.A.V.; MANGINI, A.C.S. Human parasitism by *Phagicola* sp. (Trematoda, Heterophyidae) in São Paulo State, Brazil. *Revista do Instituto de Medicina Tropical*, v. 32, n. 4, p. 285-288, 1990. Available from: <https://doi.org/10.1590/S003646651990000400008>

RECORD OF METACERCARIAE OF PARAGONIMUS BRAUN, 1899 (PLATYHELMINTHES: TREMATODA) IN THE AMAZON PROVINCE: THE SECOND ALERT OF TREMATODES AS POTENTIAL RISK TO HUMAN HEALTH IN THE STATE OF PARÁ, BRAZIL

COSTA, H.M.A.; LIMA, W.S.; COSTA, J.O. *Phagicola arnaldoi* (Travassos, 1928) Travassos, 1929 (Trematoda, Heterophyidae) em *Canis familiaris*. **Arquivo Brasileiro de Medicina Veterinária e Zootecnia**, v. 36, p. 591-595, 1984. Available from: <https://www.scielo.br/j/abmvz/>. Accessed on: 15 Jan. 2024.

COSTA, G.M.M.; RIBEIRO, H.M.C.; PANTOJA, D.N.S.M. Classificação do nível de trofia de um trecho do Rio Guamá, Belém - Pará. **Revista Geoaraguaia**, v. 12, n. 1, p. 176-191, 2022. Available from: <https://periodicoscientificos.ufmt.br/ojs/index.php/geo/article/view/11681>. Accessed on: 11 Jan. 2024.

DIAS, R.M.D.S.; MANGINI, A.C.S.; TORRES, D.M.A.G.V.; VELLOSO, S.A.G.; SILVA, R.M.; SILVA, M.I.P.G. Introdução de *Clonorchis sinensis* por imigrantes do leste asiático no Brasil e a suspensão da obrigatoriedade de exames laboratoriais para obtenção de vistos de permanência. **Revista Brasileira de Análises Clínicas**, v. 24, n. 2, p. 29-30, 1992. Available from: <https://pesquisa.bvsalud.org/portal/resource/pt/lil-119549>. Accessed on: 18 Jan. 2024.

DIAS, M.L.G.G.; EIRAS, J.C.; MACHADO, M.H.; SOUZA, F.T.; PAVANELI, G.C. The life cycle of *Clinostomum complanatum* Rudolphi, 1814 (Digenea, Clinostomidae) on the floodplain of the high Paraná River, Brazil. **Parasitology Research**, v. 89, p. 506-508, 2003. Available from: <https://doi.org/10.1007/s00436-002-0796-z>

DOANH, P.N.; SHINOHARA, A.; HORII, Y.; HABE, S.; NAWA, Y.; THE, D.T.; LE, N.T. Morphological and molecular identification of two *Paragonimus* spp., of which metacercariae concurrently found in a land crab, *Potamiscus tannanti*, collected in Yenbai Province, Vietnam. **Parasitology Research**, v. 100, p. 1075-1082, 2007. Available from: <https://doi.org/10.1007/s00436-006-0411-9>

DOANH, P.N.; HORII, Y.; NAWA, Y. *Paragonimus* and Paragonimiasis in Vietnam: an Update. **Korean Journal of Parasitology**, v. 51, n. 6, p. 621-627, 2013. Available from: <http://dx.doi.org/10.3347/kjp.2013.51.6.621>

DOANH, P.N.; TU, A.L.; BUI, T.D.; LOAN, T.H.; NONAKA, N.; HORII, Y.; BLAIR, D.; NAWA, Y. Molecular and morphological variation of *Paragonimus westermani* in Vietnam with records of new second intermediate crab hosts and a new locality in a northern province. **Parasitology**, v. 143, n. 12, p. 1639-1646, 2016. Available from: <https://doi.org/10.1017/S0031182016001219>

GIBODA, M.; DITRICH, O.; SCHOLZ, T.; VIENGSAY, T.; BOUAPHANH, S. Human *Opisthorchis* and *Haplorchis* infections in Laos, **Transactions of the Royal Society of Tropical Medicine and Hygiene**, v. 85, n. 4, p. 538-540, 1991. Available from: [https://doi.org/10.1016/0035-9203\(91\)90248-W](https://doi.org/10.1016/0035-9203(91)90248-W)

LEMOS, A.C.M.; COELHO, J.C.; MATOS, E.D.; MONTAL, G.; AGUIAR, F.; BADARÓ, R. Paragonimiasis: first case reported in Brazil. **Brazilian Journal of Infectious Diseases**, v. 11, n. 1, p. 153-156, 2007. Available from: <https://doi.org/10.1590/S1413-86702007000100031>

MAPBIOMAS PROJECT. Collection 8 of the Annual Land Cover and Land Use Maps of Brazil (1985-2022), **MapBiomass**, v. 1, 2023. Available from: <https://doi.org/10.58053/MapBiomass/VJJJCL>

MARTINS, D.E.G.; CINTRA, I.H.A.; MARTINS, M.G.; ALVES-JÚNIOR, F.A. presence of metacercariae of *Opisthorchis* sp. Blanchard, 1895 (Trematoda: Opisthorchiidae) in new host *Macrobrachium amazonicum* (heller, 1862), from the northern Brazil: an emerging risk to humans by the shrimp consumption. **Environmental smoke**, v. 6, n. 2, p. 36-45, 2023. Available from: <https://doi.org/10.32435/envsmoke-2023-0016>

OLIVEIRA, P.M.A.; PIRES, P.R.R.; GINJA, M.J.; PIRES, I.; CARDOSO, L.; ANTUNES, L.; RODRIGUES, M. *Opisthorchis felineus* in cat: case report. **Arquivo Brasileiro de Medicina Veterinária e Zootecnia**, v. 57, n. 4, p. 556-558, 2005. Available from: <https://doi.org/10.1590/S0102-09352005000400020>

PINTO, H.A.; MELO, A.L. *Melanoides tuberculata* (Mollusca: Thiaridae) as an intermediate host of *Centrocestus formosanus* (Trematoda: Heterophyidae) in Brazil. **Revista do Instituto de Medicina Tropical de São Paulo**, v. 52, n. 4, p. 207-210, 2010. Available from: <https://doi.org/10.1590/S0036-46652010000400008>

PINTO, H. A.; MELO, A. L. Metacercariae of *Centrocestus formosanus* (Trematoda: Heterophyidae) in *Australoheros facetus* (Pisces: Cichlidae) in Brazil. **Revista Brasileira de Parasitologia Veterinária**, v. 21, n. 3, p. 334-337, 2012. Available from: <https://doi.org/10.1590/S1984-29612012000300032>

PHYO MYINT, E.E.; SEREEMASPUN, A.; ROCKLÖV, J.; NITHIKATHKUL, C. Discovery of Carcinogenic Liver Fluke Metacercariae in Second Intermediate Hosts and Surveillance on Fish-Borne Trematode Metacercariae Infections in Mekong Region of Myanmar. **International Journal of Environmental Research and Public Health**, v. 17, n. 11, 2020. Available from: <https://doi.org/10.3390/ijerph17114108>

RECORD OF METACERCARIAE OF PARAGONIMUS BRAUN, 1899 (PLATYHELMINTHES: TREMATODA) IN THE AMAZON PROVINCE: THE SECOND ALERT OF TREMATODES AS POTENTIAL RISK TO HUMAN HEALTH IN THE STATE OF PARÁ, BRAZIL

SIQUEIRA-BATISTA, R.; GOMES, A.P.; ALBUQUERQUE, V.S.; PINA-COSTA, A.; ROCHA-MELLO, A.; GUIMARÃES-PEREIRA, E.; RAMOS-OLIVEIRA, F.; RUBIÃO, E.C.N. História natural da infecção por *Paragonimus*: abordagem clínica e ecológica. *Pulmão*, v. 15, n. 4, p. 270-276, 2006. Available from: https://www.sopterj.com.br/wp-content/themes/_sopterj_redesign_2017/_revista/2006/n_04/10.pdf

SUGIYAMA, H.; UMEHARA, A.; MORISHIMA, Y.; YAMASAKI, H.; KAWANAKA, M. Detection of *Paragonimus* metacercariae in the Japanese freshwater crab, *Geothelphusa dehaani*, bought at retail fish markets in Japan. *Japanese Journal of Infectious Diseases*, v. 62, n. 4, p. 324-325, 2009. Available from: <https://www.niid.go.jp/niid/JJID/62/324.pdf>. Accessed on: 10 Jan. 2024.

TOLEDO, R.; ÁLVAREZ-IZQUIERDO, M.; ESTEBAN, J.G.; MUÑOZ-ANTOLI, C. Neglected food-borne trematodiasis: echinostomiasis and gastrodiscoidiasis. *Parasitology*, v. 149, n. 10, p. 1319-1326, 2022. Available from: <https://doi.org/10.1017/S0031182022000385>