



Fernanda de Cássia Pereira Barros^{1*}; *Felipe Eduardo da Silva Sobral*²; *Soraya Abrantes Pinto de Brito*¹; *Gutemberg da Silva Lima*³; *Grazielly Diniz Duarte*¹, *Gil Dutra Furtado*⁴

Abstract

Degenerative Joint Disease (DJD) or Osteoarthritis (OA) is a common disease among dogs and is characterized by being progressive, minimally inflammatory and with non-neoplastic neoproliferative alterations, which causes considerable dysfunction in all joint structures with its subsequent failure. Affected animals present lameness, reluctance to move after rest and difficulty in performing certain activities, these being the earliest common signs. The outcome of these diseases can be aggravated by: obesity, genetic predisposition, age or trauma. Its diagnosis is based on anamnesis, patient history, physical and radiographic examination. OA treatments can be surgical or conservative depending on the case and aim to relieve discomfort and delay the development of degenerative changes and it is impossible to revert to existing pathological changes.

Keywords: Dogs. Pain. Joint degeneration. Osteoarthritis.

¹Undergraduate student in Veterinary Medicine, UNINASSAU, João Pessoa, Paraíba, Brazil

²Veterinary doctor, Professor, University Center Maurício de Nassau (UNINASSAU), João Pessoa, Paraíba, Brazil

³Veterinary doctor, João Pessoa, Paraíba, Brazil

⁴Undergraduate student in Veterinary Medicine, UNINASSAU; Agronomist, Federal University of Paraíba (UFPB); PhD in Psychobiology, Federal University of Rio Grande do Norte (UFRN); Agronomist-Partner of the “Cooperativa de Serviços Técnicos do Agronegócio” (COOPAGRO), Natal, Rio Grande do Norte, Brazil

*Corresponding author: naandabarro@hotmail.com

Submitted on: 10 Mar. 2022

Accepted on: 28 Mar. 2022

Published on: 30 Apr. 2022

© Copyright 2022



1 Introduction

The Degenerative Joint Disease (DJD) or Osteoarthritis (OA) is a common disease among dogs and is characterized by being progressive, minimally inflammatory and with non-neoplastic neoproliferative changes, which provides considerable dysfunction in all joint structures with subsequent failure. Affected animals show lameness, reluctance to move after resting and difficulty performing certain activities, these being the earliest common signs. Diagnosis is based on history, physical examination, and radiographic findings occasionally confirmed by joint fluid analysis (CLARK, 1998; CALDEIRA; MUZZI; MUZZI, 2002; NELSON; COUTO, 2006).

This disease causes pain and is manifested by lameness in dogs. When OA is primary, it is due to aging, its secondary form occurs as a consequence of pre-existing orthopedic problems, such as rupture of the cranial cruciate ligament, leading to difficulty in locomotion of animals and contributing to the appearance or worsening of osteoarticular diseases (SCHMIDT, 2009; LOBOSCO, 2012; SCHULZ, 2013).

The most common early signs of OA (osteoarthritis) are: muscle stiffness, reluctance to exercise, muscle atrophy, reduced range of motion, depression, inappetence, anorexia, inactivity, biting or licking the affected joint, local inflammation in varying degrees, restlessness, insomnia, looking for warm places and comfortable beds, difficulty getting into the defecation position; Owners also report the existence of cold claudication, which seems to resolve during periods of exercise, but worsens after rest followed by activity spikes (FOX, 2010; SCHULZ, 2013; PETTITT; GERMAN, 2015; GOLDBERG, 2017).

The result of these diseases can be aggravated by: obesity, genetic predisposition, age or trauma. Its diagnosis is made based on anamnesis, patient history, physical and radiographic examination. On physical examination, joint pain, decreased range of motion, crepitus in joint flexion and extension, and perhaps joint swelling are present (SCHMIDT, 2009; LOBOSCO, 2012). The pain stimulus is constituted by the depolarization of nociceptors due to the processes of local inflammation, which will travel through the spinothalamic pathway to the diencephalon and is propagated by the motor neuron in order to give the sensation of pain (BETTS et al. 2013). According to the International Association for the Study of Pain, pain is defined as "an unpleasant sensory and emotional experience associated with actual or potential tissue damage, or described in terms of such damage", its signs can be very subtle, and any change behavior may or may not be indicative of pain. It is necessary for the Veterinarian to know how to understand animal behavior for a better detection of a picture of pain, associated with a good physical examination and the previous history are extremely important for the diagnosis (EPSTEIN et al. 2015; LOESER; TREEDE, 2008; SARMENTO, 2014).

OA treatments can be surgical or conservative depending on the case. Its objective is to relieve discomfort and delay the development of degenerative changes and it is impossible to revert to existing pathological changes (LIPPIELLO et al., 2000).

The focus of this case report is to understand the importance of a thorough pain assessment and how it is directly linked to the animal's well-being. As well as addressing the most used conservative pharmacological treatment strategies in the treatment of long-term pain.

2 Methodology

This study followed the ethical norms of Brazilian Federal Law nº11.794/2008, Normative Resolution nº41/2021 (dogs and cats) and Ethics Committee of the UNINASSAU.

3 Case report

On July 9, 2020, a six-year-old female Shih-tzu dog was seen at a veterinary clinic located in João Pessoa in the State of Paraíba, with clinical signs of pain and lameness. pelvic limbs. The dog had been showing these changes and complaints for a while. Imaging tests were performed to better evaluate the case (Figure 1).

The radiographic examination was performed in the lateral and ventrodorsal projection of the hip joint (Figure 1), in which there was a finding suggestive of (discrete) subluxation of the right hip joint, associated with a slight indication of DJD that may be directly linked to dysplasia. Findings suggestive of tendon injuries (tendinopathy) and possible right patellar dislocation were also seen. At clinical criteria, more additional radiographic projections were suggested for better diagnostic elucidation. Then, a mediolateral and dorsoplantar projection of the left pelvic limb was performed, in which there were no clinical findings of importance for the characterization of the case.

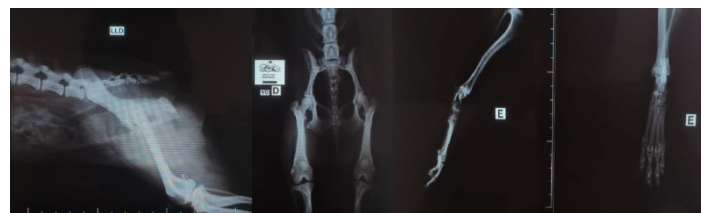

Figure 1. Radiographic images in lateral/ventrodorsal projections of the right hip joint and mediolateral/dorsoplantar of the left pelvic limb. Evidencing discrete joint degeneration suggestive of dysplasia and possible right patellar dislocation. Source: Provided and authorized by the tutor.

All projections were performed without chemical restraint of the patient. On physical examination, the drawer effect was noted, which consists of cranial translation of the tibia in relation to the femur greater than 2 mm.

Treatment was prescribed to relieve symptoms was conservative and all medications were taken orally, the drugs were: non-steroidal anti-inflammatory (Maxicam® Veterinary) 0.5 mg, 1 tablet a day for 7 days, tramadol -

opioid (Cronidor®) 10 mg, 1 tablet every 8 hours and Dipirona® 1 drop/kg every 6 hours.

Dipirona® has analgesic, antipyretic and antispasmodic effects. Although this drug is classified as an NSAID, its anti-inflammatory effect is mild when compared to NSAIDs and steroidal anti-inflammatory drugs. As for meloxicam, it is one of the most used NSAIDs for the treatment of pain in small animals due to the low incidence of side effects and its proven analgesic efficacy in the canine species (TATSUO et al., 1994; MATHEWS et al., 2001; IMAGAWA, 2006).

Tramadol can be considered an opioid and is commonly used to control painful conditions of acute or chronic origin of mild to moderate intensity in dogs. However, its use is still controversial, there are studies that indicate high variability in the response between dogs that may be due to variable metabolism as a result of genetic differences, drug interactions or other extrinsic influences (KÖGEL, B.; TERLINDEN, R.; SCHNEIDER, 2014).

After the required treatment time, the patient continued to show the signs reported in the consultation, so Gabapentin® 35mg was prescribed, 1 tablet every 12 hours for 30 days. However, it was reported by her tutor, unsatisfactory sedative effects with the use of this medication and it was suspended, and the evaluation of a physical therapist was requested.

For the long-term treatment of pain, the use of Gabapentin® is a good option. Despite its minor side effects, a sedative effect on the patient is present at the beginning of treatment (VOLLMER; Von HODENBERG; KÖLLE, 1986).

On July 22nd, 2020, the follow-up with physiatry began, where some techniques were defined for the case, such as: Laser therapy at specific points, Therapeutic Ultrasound (TUS) and specific exercises for muscle strengthening (Figure 2). The veterinary joint supplement Condroton® 500mg was also prescribed, 1 tablet a day for 60 days and the evolution of the condition was observed.




Figure 2. Local application of Therapeutic Ultrasound (TUS). Source: Image provided and authorized by the tutor.

Laser therapy is an excellent and non-invasive way to reduce pain, they are well tolerated in dogs and cats even those with a higher level of pain. It has been showing positive and promising results in pain control and has been shown to be effective in the ability to stimulate chondrocytes to produce collagen.

Therapeutic ultrasound is another physical therapy modality that can contribute to physical rehabilitation. The device is capable of producing heat during treatment, which helps control pain and joint stiffness due to soft tissue relaxation and improves synovial fluid fluidity, thus

decreasing pro-inflammatory mediators (MILLIS; LEVINE, 2014; MANGUEIRA et al., 2015; JIA et al. 2016).

The use of nutraceuticals has been widespread in integrative veterinary medicine with immunomodulatory function for the prevention of various diseases, improving the animal's quality of life and providing longevity. Glucosamine and chondroitin sulfate are chondroprotective nutraceuticals and are among the non-invasive treatments proposed to repair articular cartilage damage caused in DJD (CHARD; DIEPPE, 2001).

For not responding as expected to conservative therapy, on October 2nd, 2020, the Shih-tzu underwent a surgical procedure to resolve the drawer movement. The method used was extracapsular: the modified TightRope technique was used on the left hind limb, in which nylon thread is used to replace the fiber thread used in the original technique and the Fabelofibial Suture in the right hind limb (Figure 3). Joint stabilization is of immediate effect, offering functional recovery by reducing cranial displacement and internal rotation of the fibula.

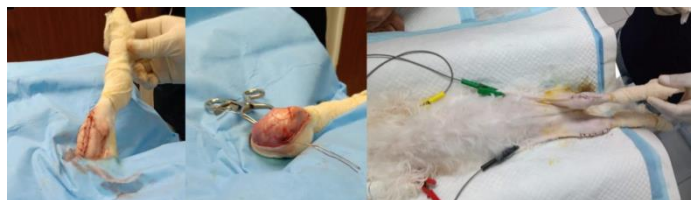


Figure 3. Creation of bone tunnels for the passage of orthopedic buttons and Cutaneous synthesis of the holes created, characterizing a minimally invasive procedure. Source: Image provided and authorized by the tutor.

However, on November 7th, 2020, the patient returned to limp and a new image exam was carried out. The projections performed were direct lateral and ventrodorsal of the pelvis region. And the diagnostic findings were an increase in soft tissue volume in the lateral region of the right pelvic limb – adjacent to the knee joint (Figure 4).

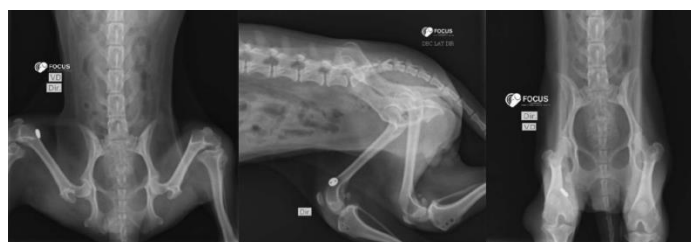

Figure 4. Radiographic images in the ventrodorsal projections of the pelvis region and right-side showing swelling in the knee region, suggestive of loosening of the extracapsular orthopedic buttons. Source: Image provided and authorized by the tutor.

As the picture for pain did not obtain a positive response, the patient underwent a new medical consultation on December 12, 2020, where the use of CBD was requested to assist in the treatment of pain. The responsible veterinarian made a request report attesting for the due purposes that the described animal has DJD in which he feels a lot of pain and inability to walk. *Cannabis* Extract ssp. rich in CBD 5 mg combined with Tetrahydrocannabinol (THC) 0.2% and olive oil vehicle. The first prescribed dose of CBD was 0.5%, 3 drops every

12 hours of continuous use. As it is a medication for use under special control by ANVISA (Brazilian Health Regulatory Agency), the tutor had to register on the laboratory's website, fill in a Term of Filing available there and attach the medical report to the form for the request to release the medication.

On February 08, 2021, the patient returned for evaluation. Her tutor reported considerable improvement in clinical signs of claudication pain. The patient who previously avoided moving around started taking walks in the neighborhood without complaints of pain. For laboratory reasons, the production of CBD at 0.5% was terminated, thus producing a new concentration of the drug - *Cannabis* Extract ssp. rich in CBD 10mg combined with Tetrahydrocannabinol (THC) 0.2% and olive oil vehicle. The new prescribed dose of CBD was 1%, 2 drops, twice daily for continuous use. The medication Traumeel 5 drops was also prescribed, twice a day of continuous use and physiotherapy sessions once a week.

Traumeel S® is a homeopathic complex that is indicated in the treatment of inflammatory and degenerative processes through a formulation with botanical species (*Arnica montana*; *Calendula officinalis*; *Hamamelis virginiana*; *Achillea millefolium*; *Atropa belladonna*; *Aconitum napellus*; *Chamomilla recutita*; *Symphytum officinale*; *Bellis perennis*; *Echinacea angustifolia*; *Echinacea purpurea*; *Hypericum perforatum*) and mineral substances (Mercurius solubilis Hahnemanni; Hepar sulfuris) in minimal therapeutic doses (HEEL, 2006; FINSTERBUSCH, M.; URRUTIA, 2013).

The patient had another return on April 7th, 2021 and she continues without complaints of pain when moving and without using NSAIDs, opioids or any other conventional drug used to treat pain. Since then, the patient has been performing a weekly physiotherapy session and using CBD at 1%, 2 drops twice a day, together with Traumeel® 5 drops twice a day, Omega 3 (Ograx® Veterinary) 500 mg, once a day. Veterinary joint supplement (Condroton®) of 500 mg, 1 tablet every other day and manipulated nutraceutical based on UCII 20mg, Piperine 86mg, Boswellia serrata 86mg, once a day and also for continuous use.

The effects of omega-3 on joints with chronic inflammation are well known, acting to decrease the magnitude of the inflammatory cascade in joints and are safe and indicated for geriatric animals (PIROTTA, 2010).

The use of type II collagen phytotherapeutic (commercially known as UC-II) promotes joint support, demonstrating great efficiency in reducing joint surface degradation, providing flexibility and mobility (DEPARLE et al., 2005; D'ALTILIO et al., 2007; GUPTA et al., 2009).

Several biological and pharmacological activities of Piperine have already been demonstrated, among them: analgesic, anti-inflammatory, antioxidant properties, antimicrobial and antifungal activity, among others (OLIVEIRA; ALENCAR-FILHO; VASCONCELLOS, 2014).

Boswellia serrata extract is used for the treatment of diseases with inflammatory characteristics, as it has a direct action in the inhibition/decrease of the synthesis of leukotrienes (LT), which are involved in the initiation and maintenance of inflammation (KE; YADAV; JU, 2012).

On May 31st, 2021, the patient (Figure 5) was re-evaluated by the physical therapist in which she suspended the therapeutic ultrasound, maintained Laser therapy and included two more therapies: Magnetotherapy and Electrotherapy for 20 minutes 2 x a week. Magnetotherapy consists of magnetic fields with a sedative effect (increase in endorphins) and a generalized relaxing effect (muscle relaxation and hypotensive action).

Electrotherapy is the application of an electric current through the skin as a form of treatment. When applied through Transcutaneous Electrical Nerve Stimulation (TENS), it aims to control pain, being considered a non-invasive and easy-to-use therapy, indicated for the control or relief of pain with acute and/or chronic characteristics (SLUKA; WALSH, 2003).



Figure 5. Patient during Magnetotherapy session. Source: Image provided and authorized by the tutor.

On June 22nd, 2021, a request was made for a new *Cannabis* oil formula where the concentration remained the same (1%) but the compounds were in a 1:1 ratio of THC/CBD, 1 drop every 12 hours for better anti-inflammatory and analgesic response.

The patient, as a carrier of DJD, a pathology with a progressive characteristic that, once diagnosed, the existing pathological changes are generally irreversible, has its clinical treatment with the objective of preventing further degenerations to avoid the evolution of the condition. Conservative drug treatment has an emphasis on relieving pain and discomfort, reducing inflammation, thus making use and medical follow-up throughout life for a better quality of life. The patient is also undergoing physical therapy rehabilitation with considerable clinical improvement, where she performs assisted walks. Magnetotherapy, Laser therapy and Electrotherapy for therapeutic purposes were also maintained and the patient has shown satisfactory results.

4 Final Considerations

Pain is directly related to the individual's well-being and reduces the patient's quality of life. The most used current pharmacological treatment is the use of NSAIDs and opioids (associated or not), however these drugs have a series of side effects that limit their use. From the results obtained, it was possible to observe the efficiency in the treatment of chronic pain with the use of analgesic compounds based on *Cannabis sativa* (either in its isolated use or associated with other drugs) with no adverse effects reported due to its continuous use. It was also possible to observe the benefits of physical therapy associated with conservative pharmacological treatment.

CREDIT AUTHORSHIP CONTRIBUTION STATEMENT

FCPB: Conceptualization, Data curation. FESS: Conceptualization, Data curation. SAPB: Formal analysis, Methodology, Project management, Writing, Validation. GSL: Formal analysis, Methodology, Project management. GDD: Project management, Writing, Formal analysis, Validation. GDR: Conceptualization, Data curation, Formal analysis, Validation.

DECLARATION OF INTEREST

The authors disclose that they have no known competing financial interests or personal relationships that could have appeared to influence the study reported in this manuscript.

FUNDING SOURCE

The authors declare that no funding is applicable for this research.

ACKNOWLEDGMENTS

The authors thank to CENTRO VETERINARIO ASSVET CASA DOS CRIADORES; to the Veterinary Service Center Dr. Edson Mauro and Consultório Veterinário Gutemberg Lima, for their contributions and guidance throughout the course of the treatment reported here.

REFERENCES

BETTS, J.G.; YOUNG, K.A.; WISE, J.A.; JOHNSON, E.; POE, B.; KRUSE, D.H.; KOROL, O.; JOHNSON, J.E.; WOMBLE, M.; DeSAIX, P. **Anatomy and Physiology**. Houston: OpenStax, 2013. Available from: <https://openstax.org/details/books/anatomy-and-physiology>.

CALDEIRA, F.M.C.; MUZZI, L.A.L.; MUZZI, R.A.L. Artrose em cães. **Caderno Técnico Veterinário e Zootécnico**, Belo Horizonte, n. 37, p. 53-83, 2002. Available from: https://www.researchgate.net/publication/284060954_Artrose_em_caes.

CHARD, J.; DIEPPE, P. Glucosamine for osteoarthritis: magic, hype, or confusion? **British Medical Journal**,

London, v. 322, p. 1439-1440, 2001. Available from: <https://doi.org/10.1136/bmj.322.7300.1439>.

CLARK, D.M. Artropatia degenerativa. In: BIRCHARD S.J.; SHERDING, R.G. (Ed.). **Manual Saunders: clínica de pequenos animais**. 2. ed. São Paulo: Roca, 1998. cap. 29, p. 1230-1233. Available from: <https://www.grupogen.com.br/editora-roca>.

D'ALTILIO, M.; PEAL, A.; ALVEY, M.; SIMMS, C.; CURTSINGER, A.; GUPTA, R.C.; CANERDY, T.D.; GOAD, J.T.; BAGCHI, M.; BAGCHI, D. Therapeutic efficacy and safety of undenatured type II collagen singly or in combination with glucosamine and chondroitin in arthritic dogs. **Toxicology Mechanisms and Methods**, London, v. 17, n. 4, p. 189-196, 2007. Available from: <https://doi.org/10.1080/15376510600910469>.

DEPARLE, L.A.; GUPTA, R.C.; CANERDY, T.D.; GOAD, J.T.; D'ALTILIO, M.; BAGCHI, M.; BAGCHI, D. Efficacy and safety of glycosylated undenatured type-II collagen (UC-II) in therapy of arthritic dogs. **Journal of Veterinary Pharmacology and Therapeutics**, Oxford, v. 28, n. 4, p. 385-390, 2005. Available from: <https://doi.org/10.1111/j.1365-2885.2005.00668.x>.

EPSTEIN, M.; RODAN, I.; GRIFFENHAGEN, G.; KADRLIK, J.; PETTY, M.; ROBERTSON, S.; SIMPSON, W. 2015 AAHA/AAFP Pain management guidelines for dogs and cats. **Journal of the American Animal Hospital Association**, Lakewood, v. 51, n. 2, p. 67-84, 2015. Available from: <https://doi.org/10.1177/1098612X15572062>.

FINSTERBUSCH, M.; URRUTIA, A.M. **Comparación del control del dolor postoperatorio en la cirugía de implantes entre Ketoprofeno y Traumeel S**. 2013. 63 f. Thesis (Master in Odontology) – Universidad Andrés Bello, Santiago, 2013. Available from: <https://repositorio.unab.cl/xmlui/handle/ria/3383>.

FOX, S.M. Pathophysiology of osteoarthritic pain. In: FOX, S.M. (Ed.). **Chronic pain in small animal medicine**. London: CRC Press, 2009. p. 74-96. Available from: <https://doi.org/10.1201/b15180>.

GOLDBERG, M.E. A look at chronic pain in dogs. **Veterinary Nursing Journal**, London, v. 32, n. 2, p. 37-44, 2017. Available from: <https://doi.org/10.1080/17415349.2016.1262217>.

GUPTA, R.C.; CANERDY, T.D.; SKAGGS, P.; STOCKER, A.; ZYRKOWSKI, G.; BURKE, R.; WEGFORD, K.; GOAD, J.T.; ROHDE, K.; BARNETT, D.; DeWEES, W.; BAGCHI, M.; BAGCHI, D. Therapeutic efficacy of undenatured type-II collagen (UC-II) in comparison to glucosamine and chondroitin in arthritic horses. **Journal of Veterinary Pharmacology and Therapeutics**, Oxford, v. 32, n. 6, p. 577-584, 2009. Available from: <https://doi.org/10.1111/j.1365-2885.2009.01079.x>.

HEEL. **Zeel® and Traumeel® Protocol to supplement current treatment with Glucosamine/Chondroitin products**. 2006. Available from: <http://www.healingedge.net/pdf/traumeel.pdf>. Accessed on: 18 mai. 2021.

- IMAGAWA, V.H. Evaluation of analgesic efficacy of dypirone by the comparison of three different doses in bitches submitted to ovariohysterectomy. 2006. 141 f. Thesis (PhD in Sciences) – Faculty of Medicine, University of São Paulo, São Paulo, 2006. Available from: <https://doi.org/10.11606/T.5.2006.tde-06022007-091127>.
- JIA, L.; CHEN, J.; WANG, Y.; ZHANG, Y.; CHEN, W. Focused low-intensity pulsed ultrasound affects extracellular matrix degradation via decreasing chondrocyte apoptosis and inflammatory mediators in a surgically induced osteoarthritic rabbit model. *Ultrasound in Medicine and Biology*, Chicago, v. 42, n. 1, p. 208-219, 2016. Available from: <https://doi.org/10.1016/j.ultrasmedbio.2015.08.010>.
- KE, F.; YADAV, P.K.; JU, L.Z. Herbal medicine in the treatment of ulcerative colitis. *Saudi Journal of Gastroenterology*, Riyadh, v. 18, n. 1, p. 3-10, 2012. Available from: <https://doi.org/10.4103/1319-3767.91726>.
- KÖGEL, B.; TERLINDEN, R.; SCHNEIDER, J. Characterisation of tramadol, morphine and tapentadol in an acute pain model in Beagle dogs. *Veterinary Anaesthesia and Analgesia*, Las Vegas, v. 41, n. 3, p. 297-304, 2014. Available from: <https://doi.org/10.1111/vaa.12140>.
- LIPPIELLO, L.; WOODWARD, J.; KARPMAN, R.; HAMMAD, T.A. In vivo chondroprotection and metabolic synergy of glucosamine and chondroitin sulfate. *Clinical Orthopaedics and Related Research*, Philadelphia, v. 381, p. 229-240, 2000. Available from: <https://doi.org/10.1097/00003086-200012000-00027>.
- LOBOSCO, A.C. *Tratamento da osteoartrose em cães: Revisão de literatura*. 2012. 45 f. Monograph (Specialization in Small Animal Medical Clinic) – Universidade Federal Rural do Semi-Árido, Niterói, 2012. Available from: <https://silo.tips/download/tratamento-da-osteoartrose-em-caes-revisao-de-literatura>.
- LOESER, J.D.; TREEDE, R.D. The Kyoto protocol of IASP basic pain terminology. *Pain*, Washington, v. 137, n. 3, p. 473-477, 2008. Available from: <https://doi.org/10.1016/j.pain.2008.04.025>.
- MANGUEIRA, N.M.; XAVIER, M.; SOUZA, R.A.; SALGADO, M.A.C.; SILVEIRA JÚNIOR, L.; VILLAVARDE, A.B. Effect of low-level laser therapy in an experimental model of osteoarthritis in rats evaluated through Raman spectroscopy. *Photomedicine and Laser Surgery*, New Rochelle, v. 33, n. 3, p. 145-153, 2015. Available from: <https://doi.org/10.1089/pho.2014.3744>.
- MATHEWS, K.A.; PETTIFER, G.; FOSTER, R.; McDONELL, W. Safety and efficacy of preoperative administration of meloxicam, compared with that of ketoprofen and butorphanol in dogs undergoing abdominal surgery. *American Journal of Veterinary Research*, Schaumburg, v. 62, n. 6, p. 882-888, 2001. Available from: <https://doi.org/10.2460/ajvr.2001.62.882>.
- MILLIS, D.L.; LEVINE, D. *Canine rehabilitation and physical therapy*. 2. ed. Philadelphia: Saunders. 2014. Available from: <https://www.sciencedirect.com/book/9781437703092/canine-rehabilitation-and-physical-therapy#book-description>.
- NELSON, R.W.; COUTO, C.G. Distúrbios das articulações. In: NELSON, R.W.; COUTO, C.G. (Ed.). *Medicina interna de pequenos animais*. 3. ed. São Paulo: Elsevier, 2006. p. 1045-1058. Available from: <https://www.elsevier.com/>.
- OLIVEIRA, R.G.; ALENCAR-FILHO, E.B.; VASCONCELLOS, M.L.A.A. The influence of piperine on the bioavailability of drugs: a molecular approach. *Química Nova*, São Paulo, v. 37, n. 1, p. 69-73, 2014. Available from: <https://doi.org/10.1590/S0100-40422014000100013>.
- PETTITT, R.A.; GERMAN, A.J. Investigation and management of canine osteoarthritis. In *Practice*, London, v. 37, n. S1, p. 1-8, 2015. Available from: <https://doi.org/10.1136/inp.h5763>.
- PIROTTA, M. Arthritis disease: The use of complementary therapies. *Australian Family Physician*, Melbourne, v. 39 n. 9, p. 638-640, 2010. Available from: <https://www.racgp.org.au/afp/2010/september/arthritis-disease-the-use-of-complementary-therapi>.
- SARMENTO, F.M. *Acupuntura no tratamento da dor em cães e gatos*. 2014. 47 f. Monograph (Bachelor in Veterinary Medicine) – Faculdade de Veterinária, Universidade Federal do Rio Grande do Sul, Porto Alegre. 2014. Available from: <https://lume.ufrgs.br/handle/10183/110078>.
- SCHMIDT, K.M. *Osteoarticular diseases in small animals*. 2009. 20 f. Monograph (Bachelor in Veterinary Medicine) – Faculdade de Medicina Veterinária e Zootecnia, Universidade Estadual Paulista, Botucatu, 2009. Available from: <https://hdl.handle.net/11449/121102>.
- SCHULZ, K.S. Diseases of the Joints. In: FOSSUM, T.W. (Ed.). *Small Animals Surgery*. 4. ed. Saint Louis: Elsevier Mosby, 2013. p. 1323-1342. Available from: <https://www.elsevier.com/>.
- SLUKA, K.A.; WALSH, D. Transcutaneous electrical nerve stimulation: Basic science mechanisms and clinical effectiveness. *The Journal of Pain*, Annapolis, v. 4, n. 3, p. 109-121, 2003. Available from: <https://doi.org/10.1054/jpai.2003.434>.
- TATSUO, M.A.K.F.; CARVALHO, W.M.; SILVA, C.V.; MIRANDA, A.E.G.; FERREIRA, S.H.; FRANCISCHI, J.N. Analgesic and antiinflammatory effects of dypirone in rat adjuvant arthritis model. *Inflammation*, New York, v. 18, n. 4, p. 399-405, 1994. Available from: <https://doi.org/10.1007/BF01534437>.
- VOLLMER, K.O.; Von HODENBERG, A.; KÖLLE, E.U. Pharmacokinetics and metabolism of gabapentin in rat, dog and man. *Arzneimittelforschung*, Stuttgart, v. 36, n. 5, p. 830-839, 1986. Available from: <https://pubmed.ncbi.nlm.nih.gov/3730018/>.