





THE OCCURRENCE OF BILATERAL CRYPTORCHIDISM IN CATS

José Andreey Almeida Teles^{1*}; Gil Dutra Furtado²

Abstract

Cryptorchidism is a reproductive alteration in males, characterized by the absence of displacement of one or both testicles from the abdominal cavity to the scrotum. The diagnosis must be made through visual inspection and careful palpation of the scrotum. A male cat, six months old, SRD, weighing 2.7 kg, was seen at a Veterinary Clinic in Arapiraca/AL, weighing 2.7 kg, for a routine medical consultation. Upon palpation, when walking the physical examination, it was observed that the patient did not have testicles in the scrotum. The treatment of choice for cryptorchidism in this case was bilateral castration, mainly due to the fact that the pathology is hereditary. The occurrence of bilateral cryptorchidism is not common in cats, being of multifactorial etiology little described in this species due to the absence of clinical signs, compromising the animal's fertility, passing unnoticed by the owner and being little discussed in the literature.

Keywords: Testicular dystopia, Testicular removal, Surgery.

¹PhD in Veterinary Science / Federal Rural University of Pernambuco (UFRPE); Freelance Veterinary Doctor; Technical Advisor to the CRMV-PB (“Conselho Regional de Medicina Veterinária do Estado da Paraíba”); Independent Researcher, João Pessoa, Paraíba, Brazil

²Veterinary Medicine / University Center Maurício de Nassau, Paraíba (UNINASSAU), João Pessoa, Paraíba, Brazil

*Corresponding author: teles.jaa@gmail.com

Submitted on: 11 Mar. 2022

Accepted on: 23 Mar. 2022

Published on: 30 Apr. 2022

© Copyright 2022



1 Introduction

The cryptorchidism, almost called by cryptorchism, cryptorchia, testicle dystopia, empty scrotum or undescended testicle, and it's a male reproductive disturb, characterized by the absence, displacement of one or both testicles from the abdominal cavity into the scrotum (HAFEZ; HAFEZ, 2004). Unilateral cryptorchidism is the correct term for the absence of a single testicle in the scrotum, and bilateral cryptorchidism refers to the absence of both. The testicle may be retained in the pre-scrotal subcutaneous tissue, abdomen or inguinal ring area while remaining in the pre-scrotal subcutaneous tissue, abdomen, or inguinal ring area (JOHNSTON; ROOT KUSTRITZ; OLSON, 2001).

Cryptorchidism in cats is not frequently reported and appears to be uncommon (MEYERS-WALLEN, 2012), with the incidence in the species ranging from 0.76% (YATES et al., 2003) to 1.7% (TSUTSUI et al., 2004). Diagnosis should be made by visual inspection and careful palpation of the scrotum. However, excess scrotal fat and inguinal lymph nodes can be confused with an ectopic testicle (ACKERMAN, 1999). The ultrasound examination has also a great importance, as it allows locating the ectopic testicle and observing morphological changes if presents it (SANTOS; VANNUCCHI; CRISTOFOLI, 2008).

The chosen treatment for cryptorchidism is bilateral orchiectomy, as it reduces the chances of developing testicular neoplasms and the possibility of genetic transmission. Therefore, considering that the population of cats as companion animals over the years has increased significantly and because cryptorchidism in cats is not frequently reported, being an uncommon medical condition, the objective was to present and describe the risk factors. Associated, as well as the forms of diagnosis and treatment of such reproductive alteration.

2 Literature Review

Cryptorchidism is a reproductive disorder characterized by the absence of displacement of one or both testicles from the abdominal cavity to the scrotum. The testicle can be retained in any segment of this path, so that when located in the abdominal cavity, it is characterized as abdominal cryptorchidism and when in the inguinal ring, inguinal cryptorchidism. When located in the abdominal region, it is considered an ectopic testicle, and not cryptorchid (NASCIMENTO; SANTOS; EDWARDS, 2011).

The scrotal testicles are difficult to palpate in very young animals under 6 months old, so the diagnosis of cryptorchidism is usually made when cats are brought in, for neutering before one year old (BATISTA ARTEAGA et al., 2000), including as an accidental finding (CAMAPUM et al., 2014). This finding may be hereditary (RHOADES; FOLEY, 1977), but there are other causes that may be associated with the onset of cryptorchidism: infection of the umbilicus during testicular descent (ROMAGNOLI, 1991), exposure of the fetus to an increased

concentration of maternal estrogen (DEPUE; PIKE; HENDERSON, 1983) or antiandrogenic chemicals (HUTSON et al., 1994), or even maternal vitamin A deficiency during fetal development (WILSON; ROTH; WARKANY, 1953).

In cats, cryptorchidism can be unilateral or bilateral, the latter being less common. Unilateral defines the absence of a single testicle in the scrotum and bilateral refers to the absence of both testes. The position of the ectopic testicles can be pre-scrotal (BOOTHE, 2008), inguinal (in the subcutaneous tissue) (BOOTHE, 2008; FELUMLEE et al., 2012) or intra-abdominal. In subcutaneous testicles the diagnosis is by palpation (BOOTHE, 2008; CAMAPUM et al., 2014), but ultrasound is a very efficient method to locate the ectopic testicle. When the undescended testicle is intra-abdominal, the diagnosis is more difficult, but ultrasound is also a highly effective method in these cases (FELUMLEE et al., 2012). Unilateral cryptorchidism is more frequent when compared to bilateral, and the right testicle is the most frequent (KAWAKAMI et al., 1984). Unilateral cryptorchids may have reduced fertility (MANSFIELD; LAND, 2002) and bilateral cryptorchids are functionally sterile due to the harmful action of temperature on spermatogenesis, which may have implications for the reproductive capacity of these animals (FOSTER, 2012). Sexual behaviors remain, however active, as testosterone (the responsible hormone) continues to be produced.

The cryptorchid testicles are hypoplastic, degenerate over time and atrophy, becoming small. Torsion and neoplasia can occur in retained testicles (TUCKER; SMITH, 2008), the latter being more common in dogs (TICIANELLI et al., 2001). However, a cryptorchid testicle with neoplasia has already been described in a cat (TICIANELLI et al., 2001). In cryptorchid dogs, the probability of having testicular neoplasia is 13 times greater than in the rest. In cats, this probability is rare. Since testicular neoplasia, even in scrotal testicles, is quite significant in dogs over 10 years of age, the probability is considered to be quite high. In cats this change is much less common than in dogs.

The chosen treatment for cryptorchidism is bilateral castration (BOOTHE, 2008; TICIANELLI et al., 2001; CAMAPUM et al., 2014), mainly due to the fact that the pathology is hereditary (TICIANELLI et al., 2001). It is even recommended that animals that have had cryptorchid children should no longer reproduce (CHRISTENSEN, 2012). The surgical technique most used in orchiectomy is the usual one, but the incision must be made over the undescended or pre-scrotal testicle (when the undescended testicle is inguinal), moving the testicle to the incision and removing it in the conventional way (BOOTHE, 2008).

3 Methodology

This study followed the ethical norms of Brazilian Federal Law n°11.794/2008, Normative Resolution n°41/2021 (dogs and cats) and Ethics Committee of the UNINASSAU.

4 Case Report

A male cat, six months old, SRD, weighing 2.7 kg, was seen at a Veterinary Clinic in Arapiraca (State of Alagoas, Brasil) for a routine medical appointment. Upon palpation, during the physical examination, it was observed that the patient did not have the testicles in the scrotum. Laboratory tests and ultrasound of the complete abdominal region (Figure 1) and (Figure 2) were performed to locate the ectopic organ.

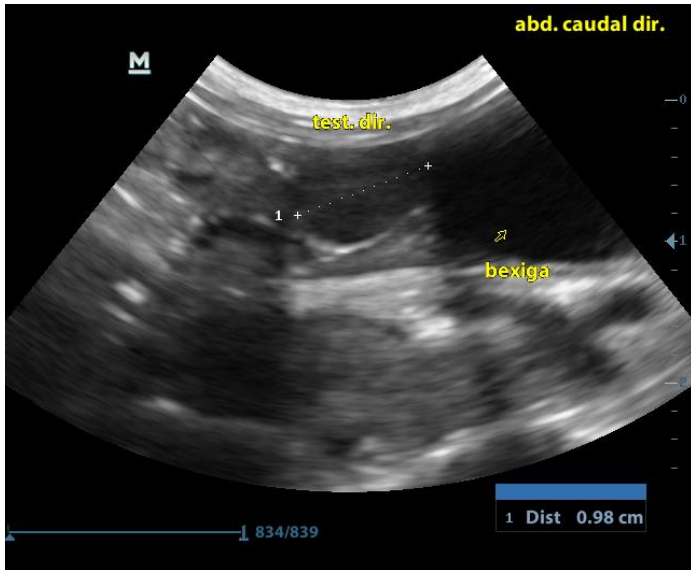


Figure 1. Ultrasound image showing right testicle measuring 0.98cm near the bladder. Source: Personal archive, 2015.

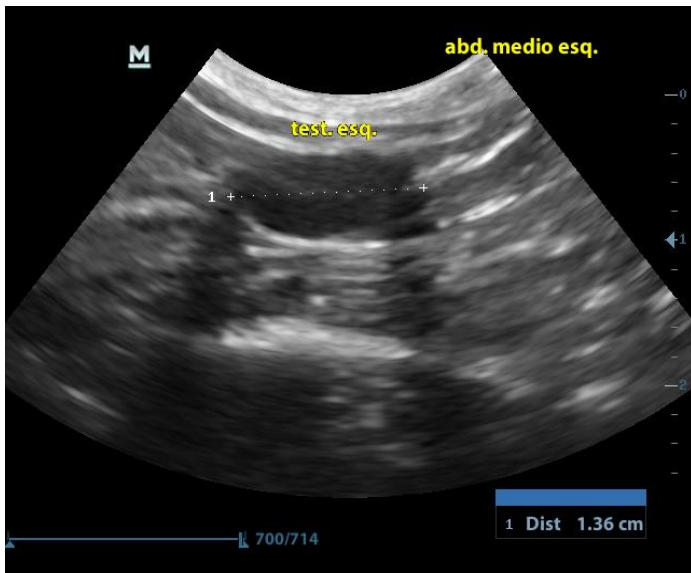


Figure 2. Ultrasound image evidencing left testicle measuring 1.36cm. Source: Personal archive, 2015.

After analysis of the exam results, surgical removal of the testicles was indicated. As pre-anesthetic medication it was administered acepromazine 0.12 mg/kg intravenously, the anesthetic induction was obtained with

the application of propofol 0.5 mg/kg intravenously and the maintenance was performed with isoflurane.

The animal was placed in dorsal decubitus position and after trichotomy and antisepsis an exploratory laparoscopy was performed and by means of conventional surgery, using the three clamps technique, hemostasis and sectioning of the testicular vessels and the ductus deferens were performed (Figure 3), using a circular ligature and another transfixing ligature with 2-0 nylon.

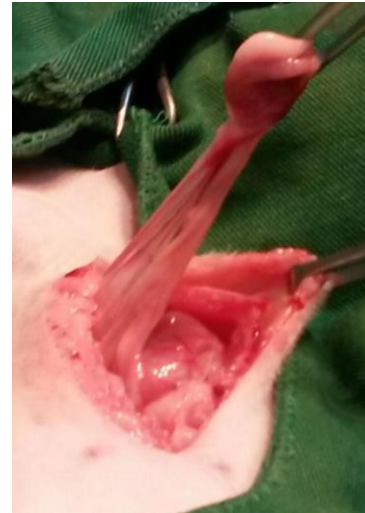

Figure 3. Testicle identification, spermatic cord and vas deferens. Source: Personal archive, 2015.

After sectioning these structures, the testicle was fully released (Figure 4) and the vascular stump returned to the abdominal cavity. By the end of the procedure, the abdomen was inspected, confirming the absence of hemorrhage. Muscle and subcutaneous tissue were occluded in a simple isolated pattern with 2-0 nylon.

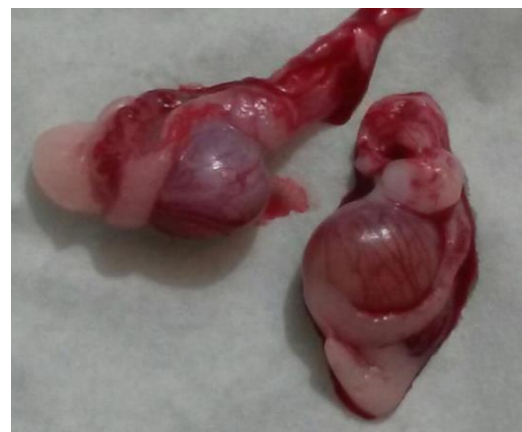

Figure 4. Testicles removed from the cryptorchid animal. Source: Personal archive, 2015.

Postoperatively, the wound was cleaned with 0.9% NaCl solution and rifamycin spray. Meloxicam (0.1mg/kg, VO, SID) was administered for 3 days and enrofloxacin (5mg/kg, VO, SID) was administered for 5 days, and the use of an Elizabethan collar was recommended so that the

animal did not have access to the surgical region. After 10 days after surgery, the animal returned to the clinic for suture removal, realizing that the incision site was fully healed, and the animal was discharged.

5 Results and Discussion

The absence of testes in the scrotum observed in the patient allowed establishing the diagnosis of bilateral cryptorchidism, which was confirmed in exploratory laparotomy. As observed in other reports (ARAUJO et al., 2013; CAMAPUM et al., 2014), this case of cryptorchidism was an accidental and rare finding. This is probably because the cat is a pet for people who need to spend a large part of the day outside the house or who travel frequently, they provide company, but are, at the same time, more independent than other domestic animals and also as cryptorchidism does not show clinical signs, cryptorchid animals are not considered carriers of pathologies by their tutors.

Although factors such as navel infections (ROMAGNOLI, 1991), maternal exposure to chemical agents (HUTSON et al., 1994), fetal exposure to maternal estrogen (DEPUE; PIKE; HENDERSON, 1983) and vitamin A deficiency (WILSON; ROTH; WARKANY, 1953), may be involved in the etiology of cryptorchidism, it was not possible to determine whether such factors were responsible in the animal in this report. According to Rojas and Walker (ROJAS; WALKER, 2012) most congenital malformations, such as cryptorchidism, are due to unknown causes usually multifactorial. Verlegen (VERTEGEN, 2004) says that there is no evidence of a hereditary cause in cats, but Ticianelli (TICIANELLI et al., 2011) and Christensen (CHRISTENSEN, 2012), say that this condition is hereditary and recommends the removal of these animals from breeding.

The data collected through a good anamnesis, clinical examination and especially an ultrasound examination are of great importance to arrive and confirm a diagnosis, since the ultrasound examination allows us to identify the ectopic testicle, as well as morphological changes in addition to guiding us during the surgical procedure.

6 Conclusions

The occurrence of bilateral cryptorchidism is not common in cats, being of multifactorial etiology little described in this species due to the absence of clinical signs, compromising the animal's fertility, going unnoticed by the owner and being little discussed in the literature.

CREDIT AUTHORSHIP CONTRIBUTION STATEMENT

The authors declare that they have been responsible for every phase of this research, including Conceptualization, Data curation, Formal analysis, Methodology, Project administration, Writing and Validation.

DECLARATION OF INTEREST

The authors disclose that they have no known competing financial interests or personal relationships that could have appeared to influence this study.

FUNDING SOURCE

The authors declare that no funding is applicable for this research.

REFERENCES

- ACKERMAN, L. Reproductive Disorders. In: ACKERMAN, L. (Ed.). **The Genetic Connection: A guide to health problems in purebred dogs**. Lakewood: American Animal Hospital Association Press, 1999. cap. 12, p. 173-175. Available from: <https://search.library.wisc.edu/catalog/9910066320902121>.
- ARAUJO, G.R.; PAULA, T.A.R.; DECO-SOUZA, T.; GARAY, R.M.; BERGO, L.C.F.; SILVA, L.C.; CSERMAK JÚNIOR, A.C.; FERRER, J.B.S.; BARROS, J.B.G. Cryptorchidism in free-living ocelot captured in the Parque Estadual do Rio Doce, Brazil. **Brazilian Journal of Veterinary and Animal Sciences**, Belo Horizonte, v. 65, n. 1, p. 1-5, 2013. Available from: <https://doi.org/10.1590/S0102-09352013000100001>.
- BATISTA ARTEAGA, M.; GONZÁLEZ VALLE, F.; CABRERA MARTÍN, F.; CALERO CARBALLO, P.O.; GRACIA MOLINA, A. Morphologic and endocrinologic characteristics of retained canine tests. **Canine Practice**, Santa Barbara, v. 25, n. 3, p. 12-15, 2000. Available from: <https://accedacris.ulpgc.es/handle/10553/73584>.
- BOOTHE, H.W. Diseases of the testes and epididymides. In: MORGAN, R.V. (Ed.). **Handbook of small animal practice**. 5. ed. Saint Louis: Saunders, 2008. p. 573-577. Available from: <https://doi.org/10.1016/B978-1-4160-3949-5.50060-1>.
- CAMAPUM, J.L.R.; FURTADO, M.D.M.; ARAÚJO, K.N.S.; MORAIS, N.M.B.; SOUSA NETO, J.B.; RODRIGUES, M.C. Criptorquidismo inguinal em felino: relato de caso. In: CONGRESSO BRASILEIRO DA ANCLIVEPA, 35., 2014, Belo Horizonte. **Anais...** Belo Horizonte, 2014. Available from: <http://www.anclivepa2014.com.br/353/341.pdf>.
- CHRISTENSEN, B.W. Disorders of sexual development in dogs and cats. **Veterinary Clinics of North America: Small Animal Practice**, Philadelphia, v. 42, n. 3, p. 515-526, 2012. Available from: <https://doi.org/10.1016/j.cvsm.2012.01.008>.

- DEPUE, R.H.; PIKE, M.C.; HENDERSON, B.E. Estrogen exposure during gestation and risk of testicular cancer. *Journal of the National Cancer Institute*, Oxford, v. 71, n. 6, p. 1151-1155, 1983. Available from: <https://doi.org/10.1093/jnci/71.6.1151>.
- FELUMLEE, A.E.; REICHLER, J.K.; HECHT, S.; PENNING, D.; ZEKAS, L.; YEAGER, A.D.; GOGGIN, J.M.; LOWRY, J. Use of ultrasound to locate retained testes in dogs and cats. *Veterinary Radiology & Ultrasound*, London, v. 53, n. 5, p. 581-585, 2012. Available from: <https://doi.org/10.1111/j.1740-8261.2011.01943.x>.
- FOSTER, R.A. Common lesions in the male reproductive tract of cats and dogs. *Veterinary Clinics of North America: Small Animal Practice*, Philadelphia, v. 42, n. 3, p. 527-545, 2012. Available from: <https://doi.org/10.1016/j.cvs.2012.01.007>.
- HAFEZ, E.S.E.; HAFEZ, B. *Reprodução animal*. 7. ed. Barueri: Manole, 2004. Available from: <https://antoniogoliveira.com/list/reproducao-animal-7-edicao/>.
- HUTSON, J.M.; BAKER, M.; TERADA, M.; ZHOU, B.; PAXTON, G. Hormonal control of testicular descent and the cause of cryptorchidism. *Reproduction, Fertility and Development*, Melbourne, v. 6, n. 2, p. 151-156, 1994. Available from: <https://doi.org/10.1071/RD9940151>.
- JOHNSTON, S.D.; ROOT KUSTRITZ, M.V.; OLSON, P.N.S. Disorders of canine testes and epididymides. In: JOHNSTON, S.D.; ROOT KUSTRITZ, M.V.; OLSON, P.N.S. (Ed.). *Canine and feline theriogenology*. Philadelphia: Saunders, 2001. p. 312-332. Available from: <https://www.worldcat.org/title/canine-and-feline-theriogenology/oclc/45087174>.
- KAWAKAMI, E.; TSUTSUI, T.; YAMADA, Y.; YAMAUCHI, M. Cryptorchidism in the dog: Occurrence of cryptorchidism and semen quality in the cryptorchid dog. *The Japanese Journal of Veterinary Science*, Tokyo, v. 46, n. 3, p. 303-308, 1984. Available from: <https://doi.org/10.1292/jvms.1939.46.303>.
- MANSFIELD, K.G.; LAND, E.D. Cryptorchidism in Florida panthers: prevalence, features, and influence of genetic restoration. *Journal of Wildlife Diseases*, Lawrence, v. 38, n. 4, p. 693-698, 2002. Available from: <https://doi.org/10.7589/0090-3558-38.4.693>.
- MEYERS-WALLEN, V.N. Gonadal and Sex Differentiation Abnormalities of Dogs and Cats. *Sexual Development*, Basel, v. 6, n. 1-3, p. 46-60, 2012. Available from: <https://doi.org/10.1159/000332740>.
- NASCIMENTO, E.F.; SANTOS, R.L.; EDWARDS, J.F. Sistema Reprodutor Masculino. In: SANTOS, R.L.; ALESSI, A.C. (Ed.). *Patologia Veterinária*. 1. ed. São Paulo: Roca, 2011. p. 855-880. Available from: <https://livraria.funep.org.br/product/patologia-veterinaria/>.
- RHOADES, J.D.; FOLEY, C.W. Cryptorchidism and intersexuality. *Veterinary Clinics of North America*, Philadelphia, v. 7, n. 4, p. 789-794, 1977. Available from: [https://doi.org/10.1016/S0091-0279\(77\)50091-3](https://doi.org/10.1016/S0091-0279(77)50091-3).
- ROJAS, M.; WALKER, L. Congenital malformations: General and genetic aspects. *International Journal of Morphology*, Temuco, v. 30, n. 4, p. 1256-1265, 2012. Available from: <http://dx.doi.org/10.4067/S0717-95022012000400003>.
- ROMAGNOLI, S.E. Canine cryptorchidism. *Veterinary Clinics of North America: Small Animal Practice*, Philadelphia, v. 21, n. 3, p. 533-544, 1991. Available from: [https://doi.org/10.1016/S0195-5616\(91\)50059-0](https://doi.org/10.1016/S0195-5616(91)50059-0).
- SANTOS, S.E.C.; VANNUCCHI, C.I.; CRISTOFOLI, M. *Criptorquidismo em cães*. 2008. Available from: <https://www.sosanimal.com.br/informativo/exibir/?id=91>. Accessed on: 17 mar. 2022.
- TICIANELLI, J.S.; OLIVEIRA, B.M.M.; ZOGNO, M.A.; ARRUDA, R.P.; CELEGHINI, E.C.C. Intersex and others development anomalies of the reproductive tract in the domestic animals and the cytogenetic as ancillary test to diagnosis. *Brazilian Journal of Animal Reproduction*, Belo Horizonte, v. 35, n. 1, p. 26-32, 2011. Available from: <http://www.cbra.org.br/portal/publicacoes/rbra/2011/rbrajm2011.html>.
- TSUTSUI, T.; KUWABARA, S.; KUWABARA, K.; KUGOTA, Y.; KINJO, T.; HORI, T. Development of Spermatogenic Function in the Sex Maturation Process in Male Cats. *Journal of Veterinary Medical Science*, Tokyo, v. 66, n. 9, p. 1125-1127, 2004. Available from: <https://doi.org/10.1292/jvms.66.1125>.
- TUCKER, A.R.; SMITH, J.R. Prostatic squamous metaplasia in a cat with interstitial cell neoplasia in a retained testis. *Veterinary Pathology*, Thousand Oaks, v. 45, n. 6, p. 905-909, 2008. Available from: <https://doi.org/10.1354/vp.45-6-905>.
- VERTEGEN, J. Reprodução em felinos. In: ETTINGER, S.J.; FELDMAN, E.C. (Ed.). *Tratado de Medicina Interna Veterinária: Doenças do cão e do gato*. 5. ed. Rio de Janeiro: Guanabara-Koogan, 2004. v. 2, p. 1670-1684. Available from: <https://www.grupogen.com.br/tratado-de-medicina-interna-veterinaria-doencas-do-cao-e-do-gato>.
- WILSON, J.G.; ROTH, C.B.; WARKANY, J. An analysis of the syndrome of malformations induced by maternal vitamin a deficiency. Effects of restoration of vitamin a at various times during gestation. *American Journal of Anatomy*, Baltimore, v. 92, n. 2, p. 189-217, 1953. Available from: <https://doi.org/10.1002/aja.1000920202>.
- YATES, D.; HAYES, G.; HEFFERNAN, M.; BEYNON, R. Incidence of cryptorchidism in dogs and cats. *Veterinary Record*, London, v. 152, n.16, p. 502-504, 2003. Available from: <https://doi.org/10.1136/vr.152.16.502>.